Pharynx

- Funnel shaped musculo-membranous tube that connect:
  - Oral cavity to esophagus
  - Nasal cavity to larynx

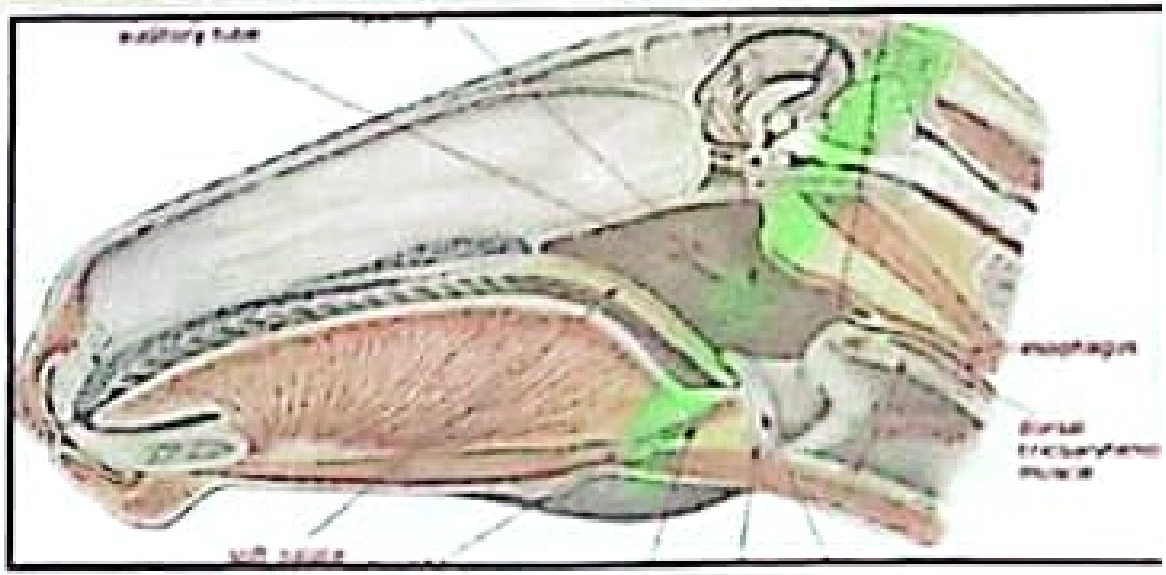

- Divided into:
  1. **Rostral part:** divided by soft palate into:
     a) Nasopharynx dorsally
     b) Oropharynx ventrally
  2. **Caudal part (laryngopharynx)**

     contain: 1- Piriform recess
     2- Entrance of esophagus
     3- Aditus laryngius

Pharynx

Piriform recess

- Narrow space present between palatopharyngeal fold and ary-epiglottic fold on each side
- Continue at the floor of oropharynx around entrance of larynx until esophagus where fluids pass through it to esophagus

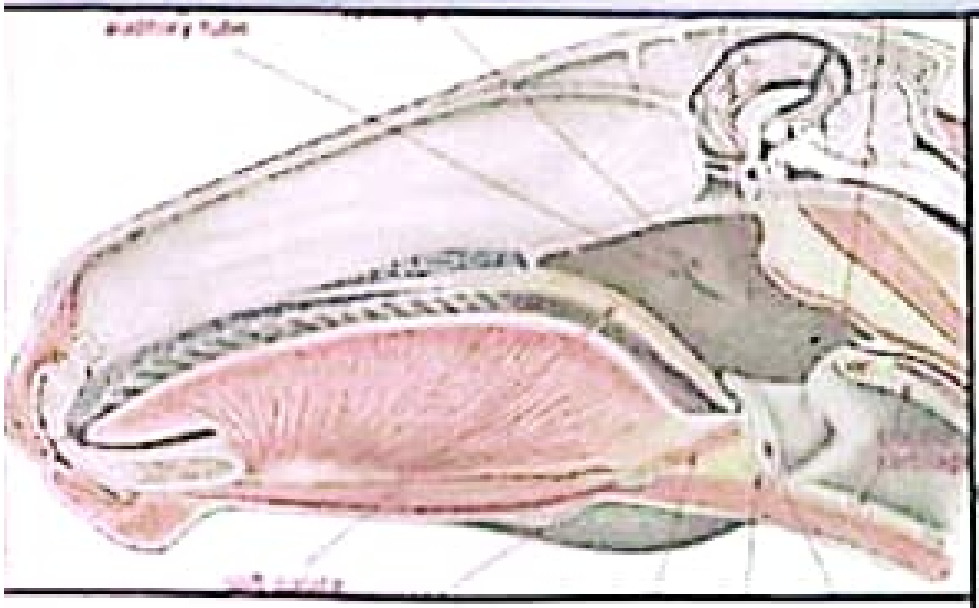

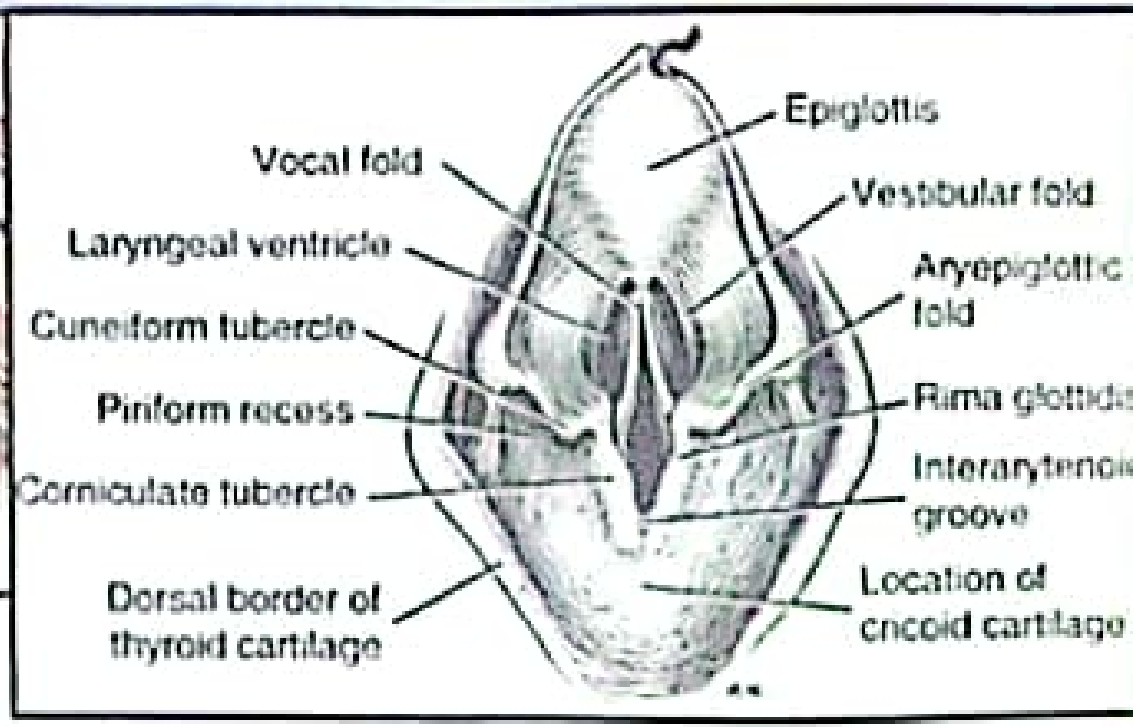

Description of three pharyngeal division

1) Nasopharynx

- ✓ Part of respiratory channel
- ✓ Separated from nasal cavity by:
  - *Horizontal plate of ethmoidal and palatine bone*
  - *Vomer bone*
- ✓ Related caudally to base of skull

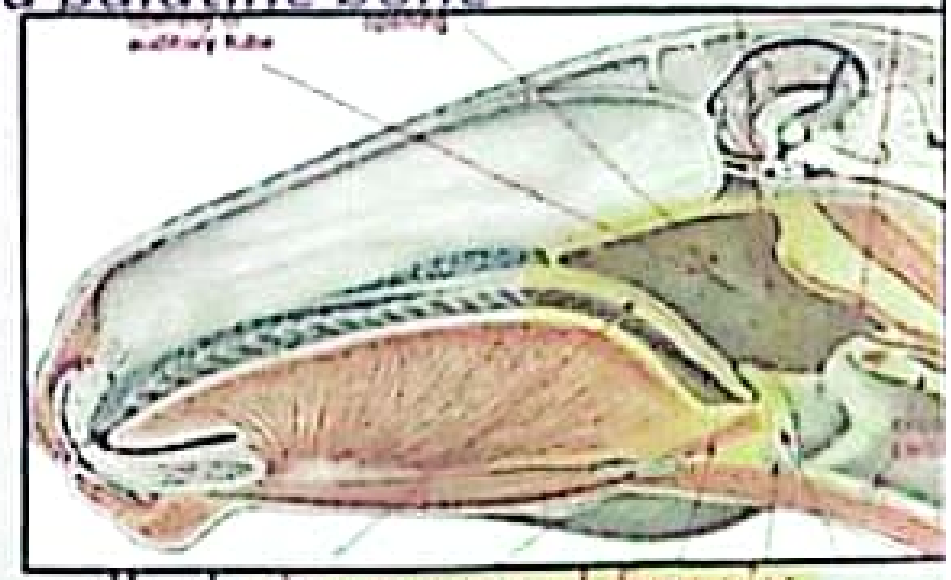

- ✓ Boundaries:
  - Floor: soft palate
  - Roof: concave in both directions, called pharyngeal fornix
    - Caudal blind sac of nasopharynx which located dorsal to guttural pouch called pharyngeal recess
  - Lateral wall: contain pharyngeal opening of auditory tube which covered by fold of m.m. called salpingo-pharyngeal fold

Opening of pharynx

I. Paired opening

1) Choanae (posterior nares = nasopharyngeal duct)
   - *Connect nasal cavity with nasopharynx*
2) Pharyngeal opening of auditory tube
   - *Connect nasopharynx with auditory tube of middle ear*

II. Single opening

1) Isthmus faucium (aditus pharyngius)
   - *Connect oral cavity with oropharyn*
   - *Bounded:*
     - *Dorsally: by soft palate*
     - *Ventrally: by root of tongue*
2) *Aditus laryngius*
3) *Entrance of esophagus*

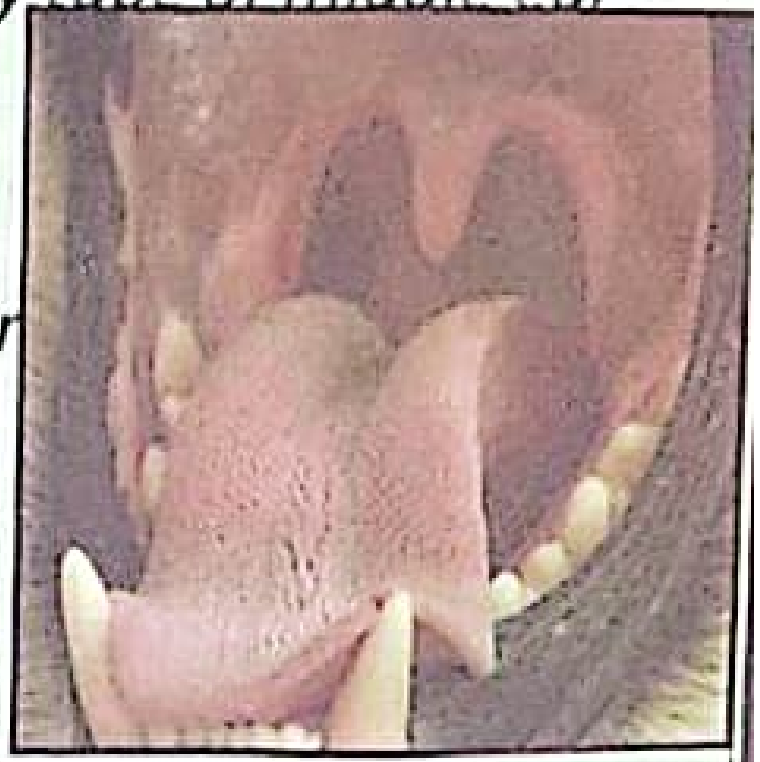

Muscles of pharynx

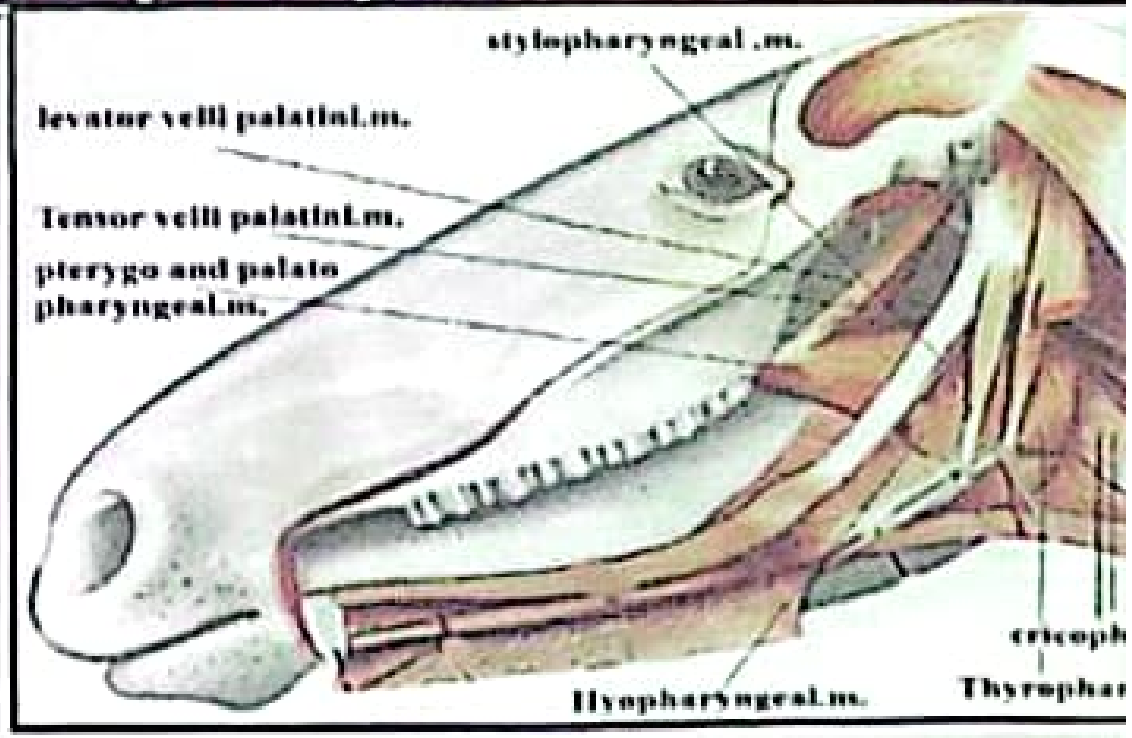

I. **Dilator group**
   - *Caudal stylo-pharyngeal*

II. **Constrictor group**

1) Rostral group
   - *Pterygo-pharyngeal*
   - *Palato-pharyngeal*

2) Middle group
   - *Stylo-pharyngeal muscle (may be abscent)*
   - *Hyo-pharyngeal muscle*

3) Caudal group
   - *Thyro-pharyngeal muscle*
   - *Crico-pharyngeal muscle*

2) Oropharynx

Boundaries:

- Roof: soft palate
- Floor: lingual root
- Lateral wall: palatoglossal arch

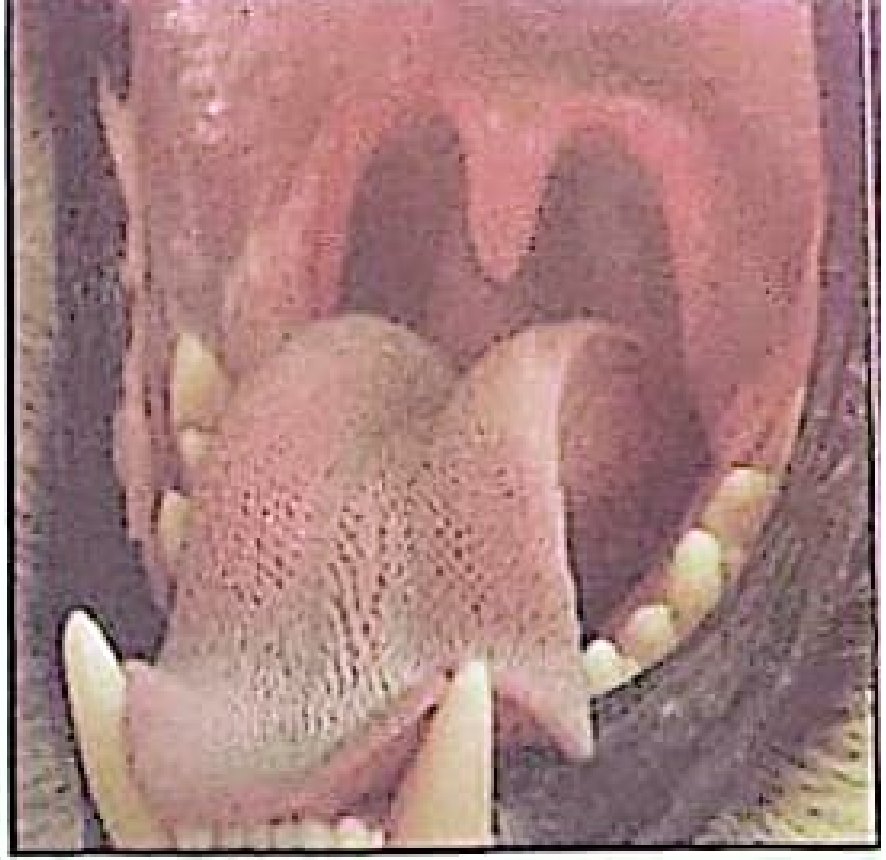

3- Laryngopharynx

- Common cavity to respiratory and digestive system
- There are three structures:
  - Two opening:
    1) *Aditus laryngius*
    2) *Entrance of esophagus*
  - Piriform recess

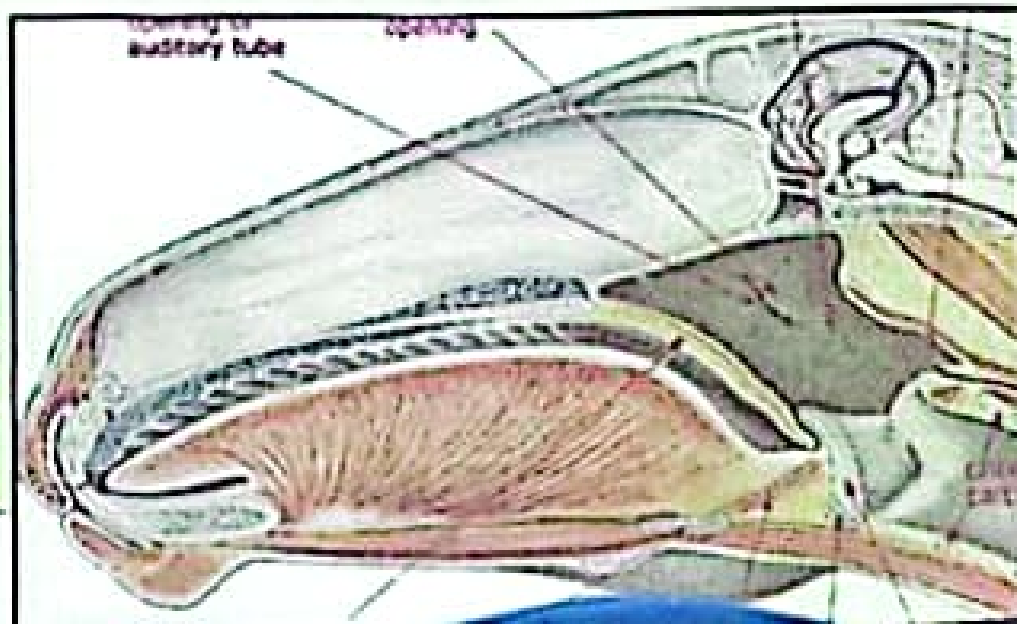

Lymphatic organs of pharynx

- Accumulation of lymphatic tissue which may be:
  1. *Diffuse non-organized lymphatic tissue*
  2. *solitary lymph nodules*
  3. *Aggregated lymph nodules*
- **When:**

Large no/of lymph nodules combined with diffuse non-organized lymphatic tissue

↓

They form independent lymphatic organs called tonsils

Tonsils named according their position:

1. Lingual tonsil
2. Palatine tonsil
3. Pharyngeal tonsil
4. Tubal tonsil
5. Tonsil of soft palate
6. Para-epiglottic tonsil

Tubal tonsil

- Located on lateral wall of pharyngeal opening of auditory tubes
- Dog: abscent

Para-epiglottic tonsil

- Small tonsil on base of epiglottis
- Abscent in: dog + ox + horse
- present: pig + small Ruminant

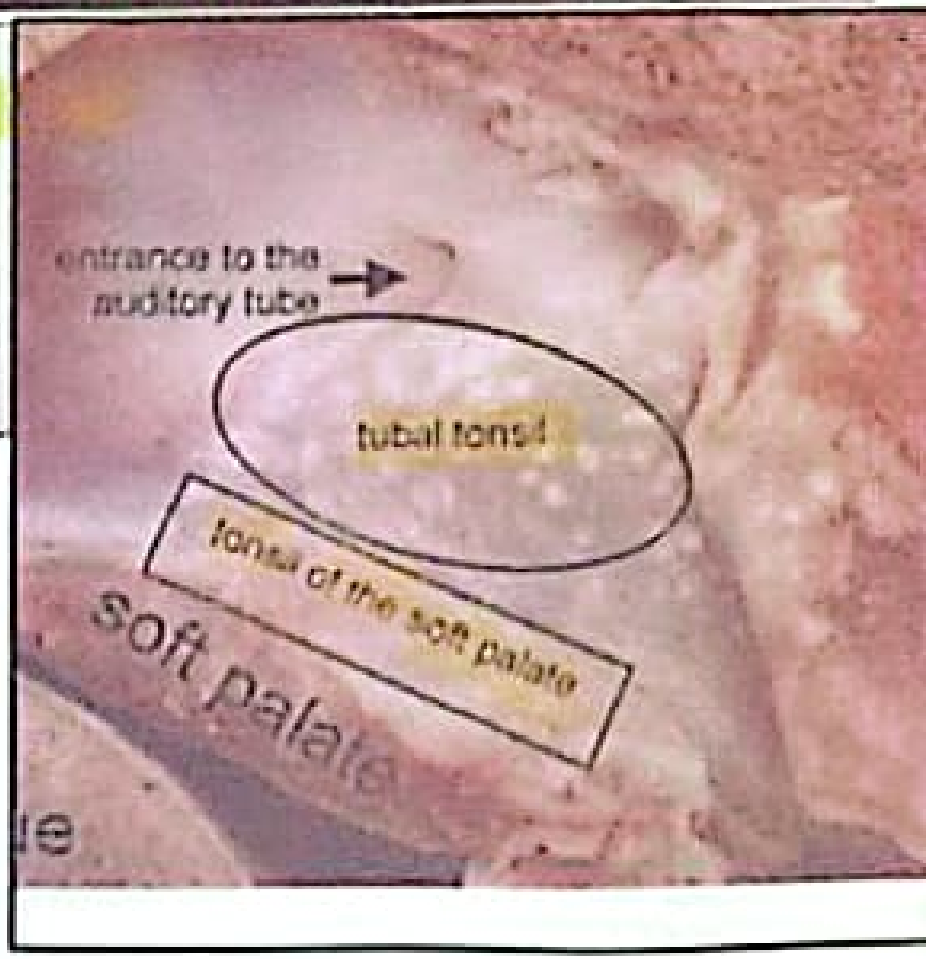

Lingual tonsil

- In mucosa of lingual root
- Dog: only diffuse lymphatic tissue + solitary nodules
- Pig: few isolated follicles
- Ruminant and horse: tonsillar follicles

Palatine tonsil

- Located in or on lateral wall of oropharynx
- Dog: located in tonsillar fossa
- Ruminant: formed from follicular tonsil with branching tonsillar sinus
- Horse: located between base of epiglottic &glossopalatine arch
- Pig: Abscent

Tonsil of soft palate

- Located on ventral surface of soft palate
- Dog: only small amount of diffuse lymphatic tissue

Pharyngeal tonsil

- Located on the roof of the nasopharynx
- Dog: flat non-follicular tonsil lie between opening of auditory tubes
- Horse: follicular tonsil lie between opening of auditory tubes
- Pig: follicular tonsil on caudal end of pharyngeal septum
- Ruminant: non-follicular tonsil on caudal end of pharyngeal septum

Esophagus

- ✓ Musculo-membranous tube connect pharyngeal cavity with stomach
- ✓ It is the direct continuation of the laryngeo-pharynx
- ✓ **Divided into three parts;**
  1. *Cervical part*
  2. *Thoracic part*
  3. *Short abdominal part*
- ✓ Esophagus is longer in horse (125-150cm) than ox (90-95)
- ✓ **The muscular wall of esophagus is:**
  - ➢ Striated throughout its entire length in case of ruminant and dog
  - ➢ While, it changes to smooth muscle in caudal third in case of horse.

Thoracic part

- ✓ Begin at thoracic inlet until 2nd th. V. it returns to its dorsal position.
- ✓ Then, it run caudally in mediastinum dorsal to tracheal bifurcation and cross to right side of aortic arch.
- ✓ **Caudal to base of heart:** esophagus lies between lung ventral to aorta
- ✓ **It accompanied by** dorsal and ventral esophageal vagal nerve trunks.
- ✓ **Finally it passes through** esophageal hiatus and terminate with very short abdominal a part at the cardia of the stomach.

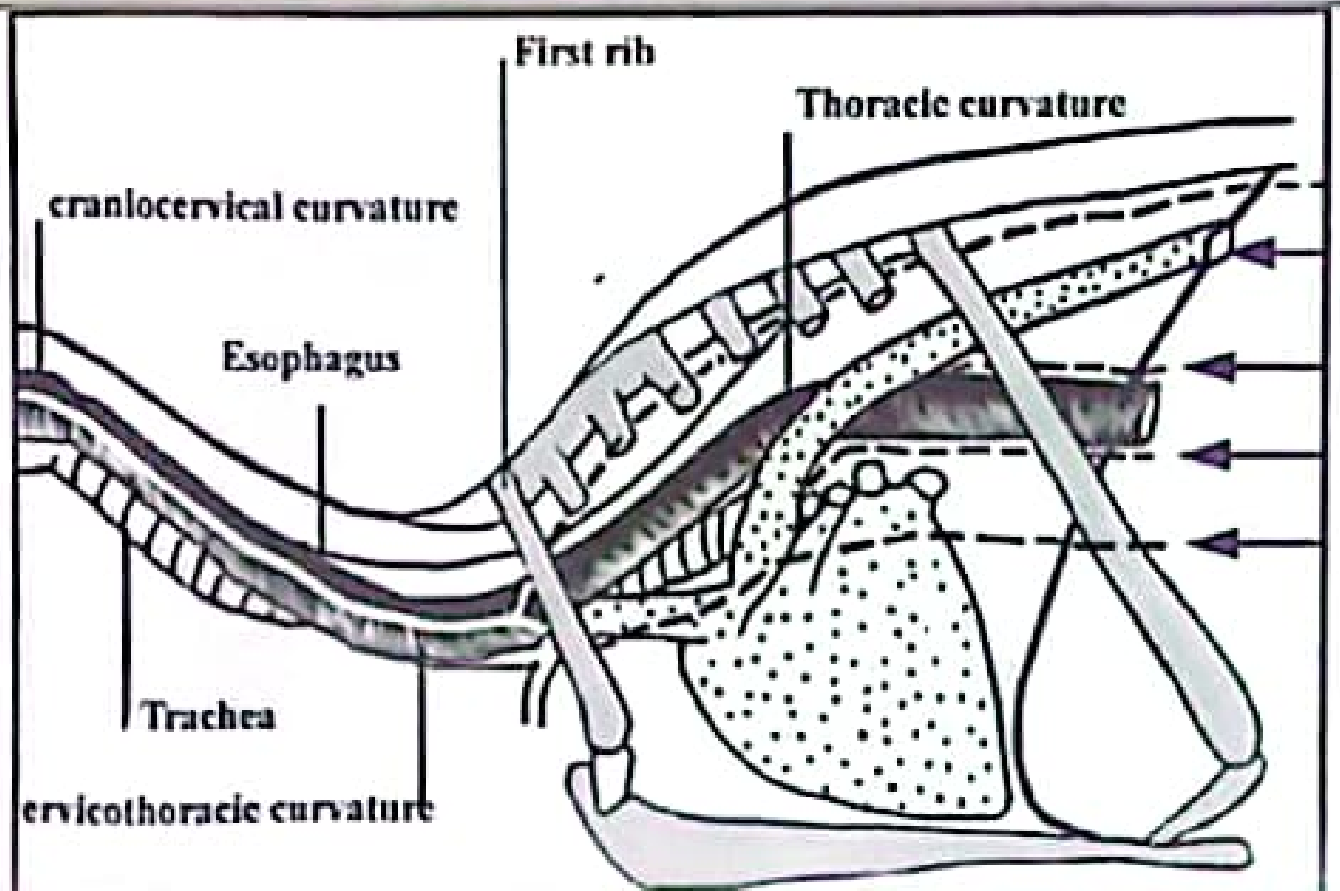

Guttural pouch
Diverticulum of auditory tube

- Present in equine + rodent + bat
- Diverticulum of m. m. of auditory tube which extending from the base of skull to the wall of pharynx in caudoventral direction and continue caudally under wing of atlas

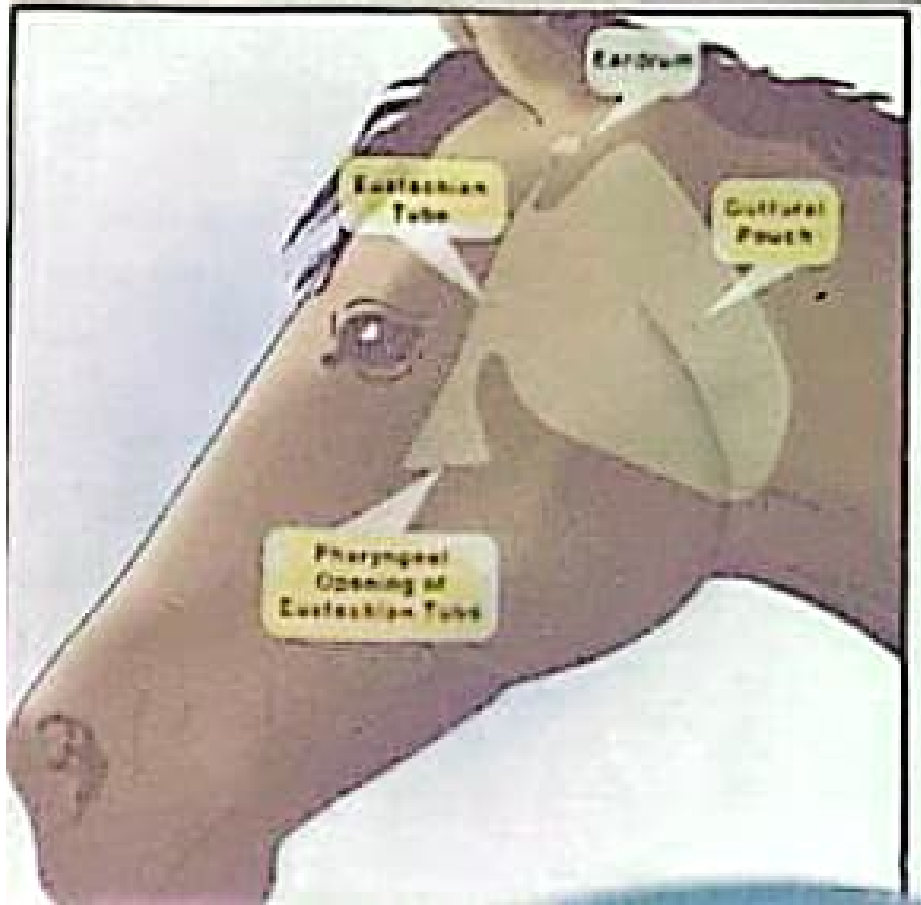

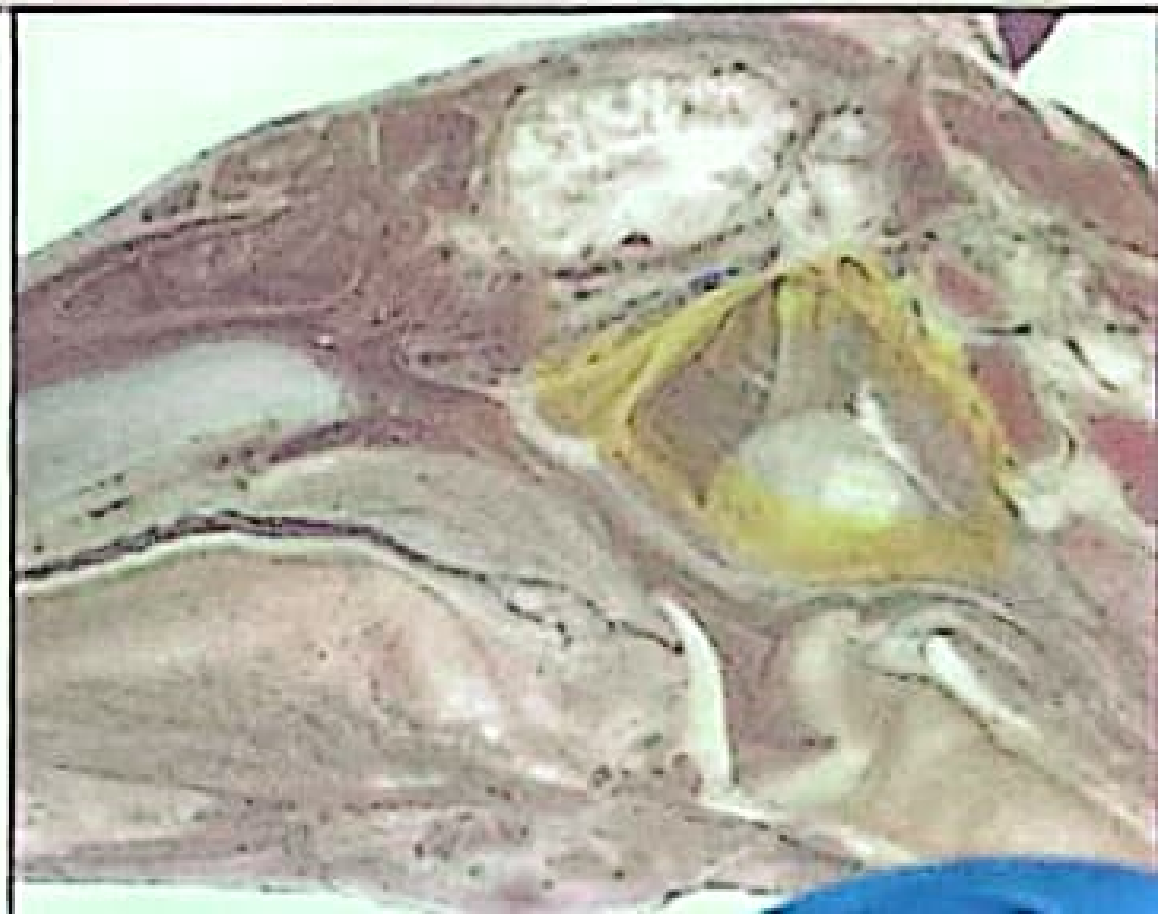

During course of esophagus, it show three curvatures:

1. **Cranial curvature**: at beginning, &appeared convex dorsally
2. **Cervico-thoracic curvature**: at thoracic inlet &concave dorsally.
3. **Thoracic curvature**: at base of heart & appear slightly convex dorsally.

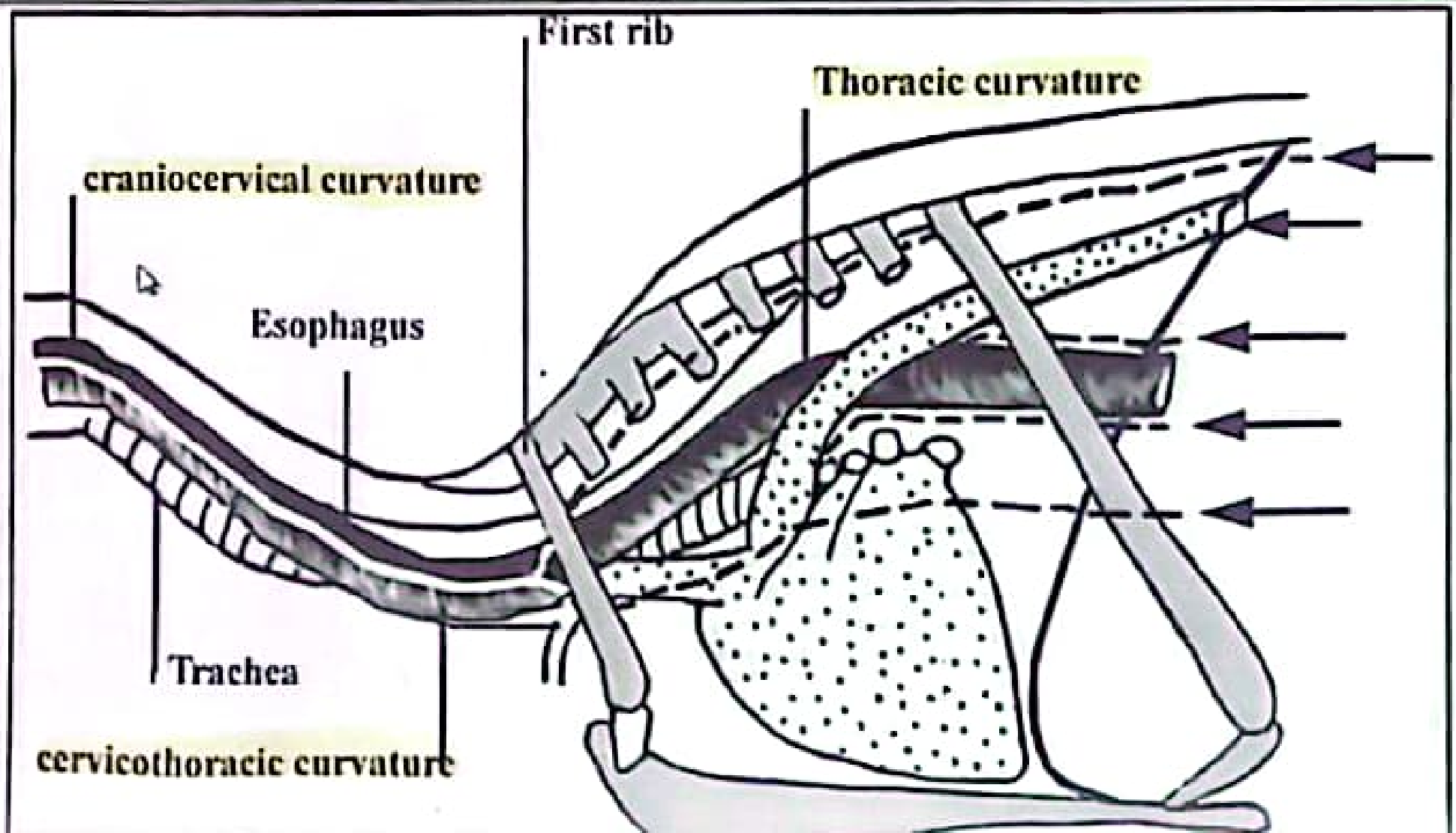

Cervical part
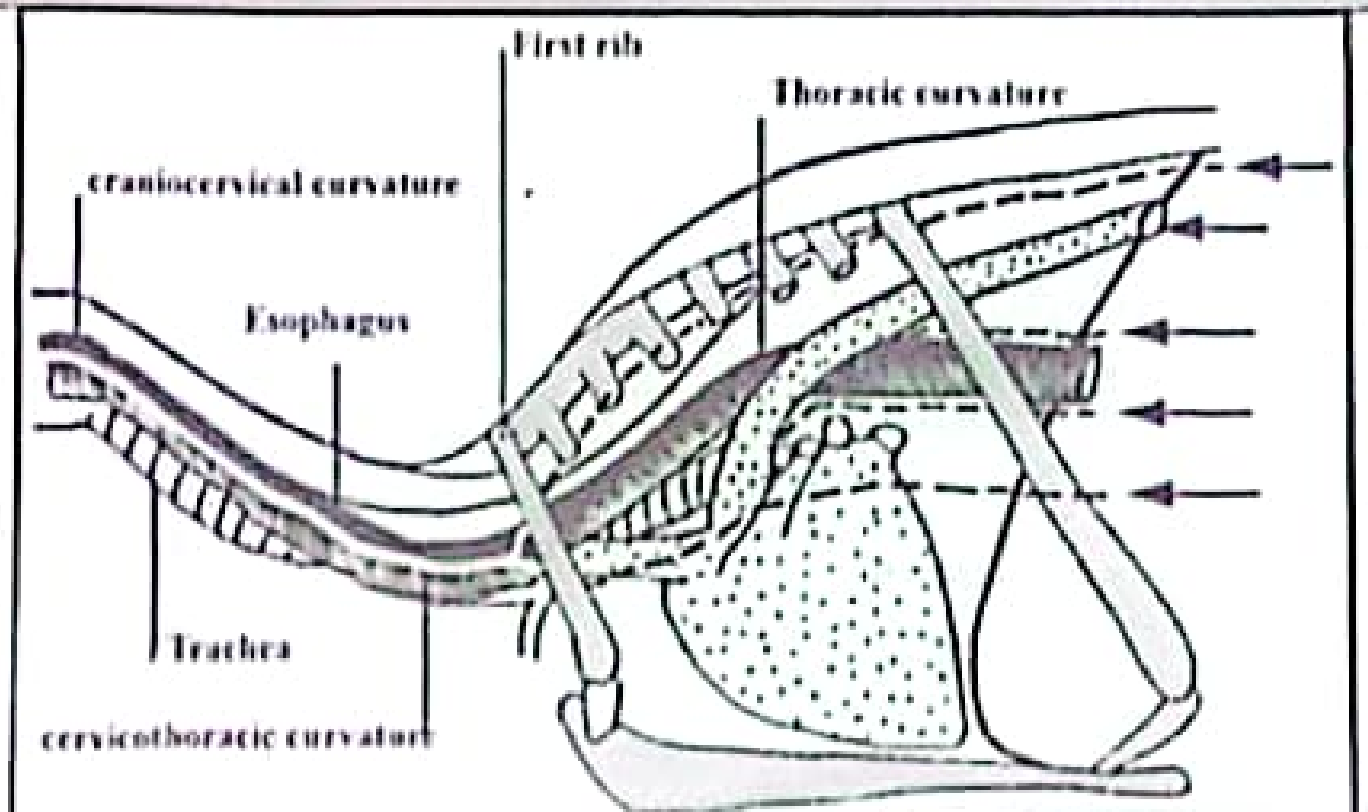
- ✓ Lies between the longus colli muscle and the trachea.
- ✓ At level of 5th cervical vertebrae in horse (3rd in ox), it shift from its median position and pass to left side of the trachea.
- ✓ The main relation are:
  - ➢ Common carotid artery + internal jugular vein
  - ➢ Trachea + tracheal duct
  - ➢ Vagosympathetic nerve trunk + recurrent laryngeal nerve
  - ➢ In the young animals the thymus gland.